

**RESEARCH ARTICLE**

**Effect of sodium valproate in  
histological features of  
cerebellum in chick embryos**

1Shabana Sultana, 2M.A.Doshi, 3N.Jayasree,

4Mrudula Chandrupatla

1. Tutor, Department of Anatomy, Apollo Institute of Medical Sciences and Research, Hyderabad, Telangana, India.

2. Professor and Head, Department of Anatomy, Krishna Institute of Medical Sciences, Karad, Maharashtra, India.

3. Dean and Professor, Department of Anatomy, Sakshi Medical College and Research Centre, Myana, Guna, M.P., India.

4. Professor and Head, Department of Anatomy, Apollo Institute of Medical Sciences and Research, Hyderabad, Telangana, India.

**Correspondence**

Shabana Sultana  
Department of Anatomy,  
Apollo Institute of Medical  
Sciences and Research,  
Hyderabad, Telangana, India

**Keywords**

Sodium Valproate, Chick  
Embryo, Cerebellum

**Received**

08 December 2016

**Reviewed**

10 December 2016

**Accepted**

14 December 2016

**ABSTRACT**

Valproic acid is an antiepileptic drug prescribed as monotherapy in newly diagnosed cases of Epilepsy. It is also useful in combating generalized Tonic-Clonic Seizures, Partial Seizures, Myoclonic Seizures. It acts by increasing the levels of the Neurotransmitter GABA in the cerebrum. Valproate inhibits sustained repetitive firing induced by depolarization of cortical or spinal cord neurons. It produces small reductions of the low-threshold(T) Calcium current at clinically relevant but slightly higher concentrations then limit sustained repetitive firing. Reducing T currents may contribute to the effectiveness of Valproic acid against partial and tonic-clonic seizures and absence seizures respectively.

In vitro, Valproate can stimulate the activity of the GABA synthetic enzyme, Glutamic Acid Decarboxylase and inhibit GABA degradative enzymes, GABA transaminases. But studies show that they cause defects in the formation of neural tube if used during pregnancy.

In the present study fertilized eggs were administered with Sodium Valproate at 24 hours of incubation and the development of Cerebellum was studied after 20 days. The histological and gross features of Cerebellum were identified.

## INTRODUCTION

The study of the Cerebellum in Chick embryo (Gallus gallus) is very important because it controls physical activities, maintenance of the balance of the organism, regulation of muscle tone (1,2). The chick brain consists of three main parts: cerebrum, cerebellum and medulla oblongata. The chick has large cerebral hemispheres and small cerebellar hemispheres (3). There are no significant differences that occur in the central nervous system of the birds compared to that of mammals (4). The cerebral hemispheres were separated from the cerebellum by a transverse fissure (5). The cerebellum in chick embryo of 20 days age consists of two components, gray matter and white matter. The gray matter is situated externally while the white matter is situated internally (6). Also, the cerebellum consists of cortex and medulla. The cortex consists of three layers: molecular layer, Purkinje cell layer and granular layer (7).

Considering the Anti Epileptic Property of Sodium Valproate, the present study was undertaken to observe and elucidate the changes in the Cerebellum after administration of Drug. The changes were considered in relation to the anti-histogenesis or anti-mitotic activity of Sodium Valproate by administering the drug into Fertilized Eggs. An attempt has been made to observe if the Drug passes through Placental Barrier leading to Malformations of Foetus. Such a study will help in treating Epilepsy Patients who are Pregnant. Sodium Valproate has been experimented by few Scientists on Laboratory animals like Chick Embryos etc. and their observations were noted.

## MATERIAL AND METHODS:

**a) SELECTION OF EGGS:** Well developed, mature and healthy fertile eggs are selected from the breeders from white leg horn (Gallus gallus). Excessively large or small eggs, cracked or thin shelled eggs are avoided because they will have difficulty in retaining moisture which is needed for proper chick development. Penetration of microorganisms increases in cracked eggs. Eggs should not be washed or wiped with clean cloth as it removes the protective coating and promotes the entry of microorganism. Rubbing and washing also serves to force disease organisms through the pores of the shell.

**b) INCUBATION OF EGGS:** It was done for a period of 24 hours

and 0.25ml of Sodium Valproate drug was injected, then the eggs were re-incubated and sacrificed on 20<sup>th</sup> day. The temperature should be

101 ° F for first week

102° F for second week

103° F for third week

Optimum growth for most of the species requires a relative humidity of 60% until eggs begin to pip, after which the relative humidity should be raised to 70%. The humidity is maintained inside the incubator by placing an open pan of water with suspending a piece of cloth from the water, proving wick action.

c) **ADMINISTRATION OF TERATOGENIC AGENTS IN TO INTACT CHICK EMBRYO:** Five eggs were kept as control and Sodium Valproate was injected into other set of five experimental eggs. A small hole over the broad end of the experimental egg was made using 22-gauge needle. 0.25 ml of Sodium Valproate was injected into the egg after 48 hours of incubation. It was done with an insulin syringe .Following drug administration, the holes were sealed with molten wax after which the eggs were placed back into the incubator

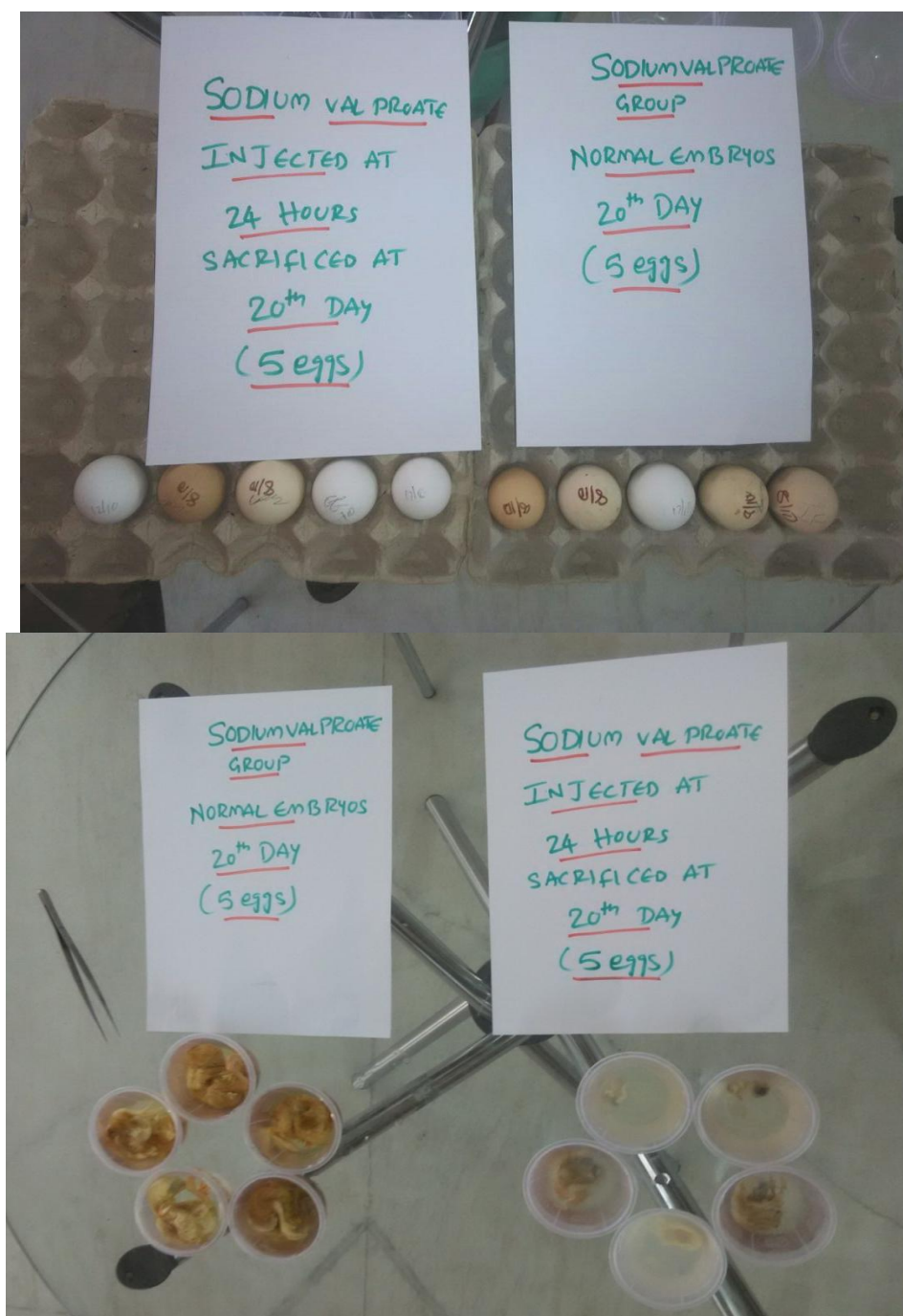
d) **PROCESSING AND STAINING:** After 20 days of incubation the eggs are broken and the embryo is collected and fixed in 10% formalin solution for 48 hrs. The cerebellum tissue is separated, processed and stained with Haematoxylin and eosin stains. The slides are studied under the simple

microscope and various features are identified.

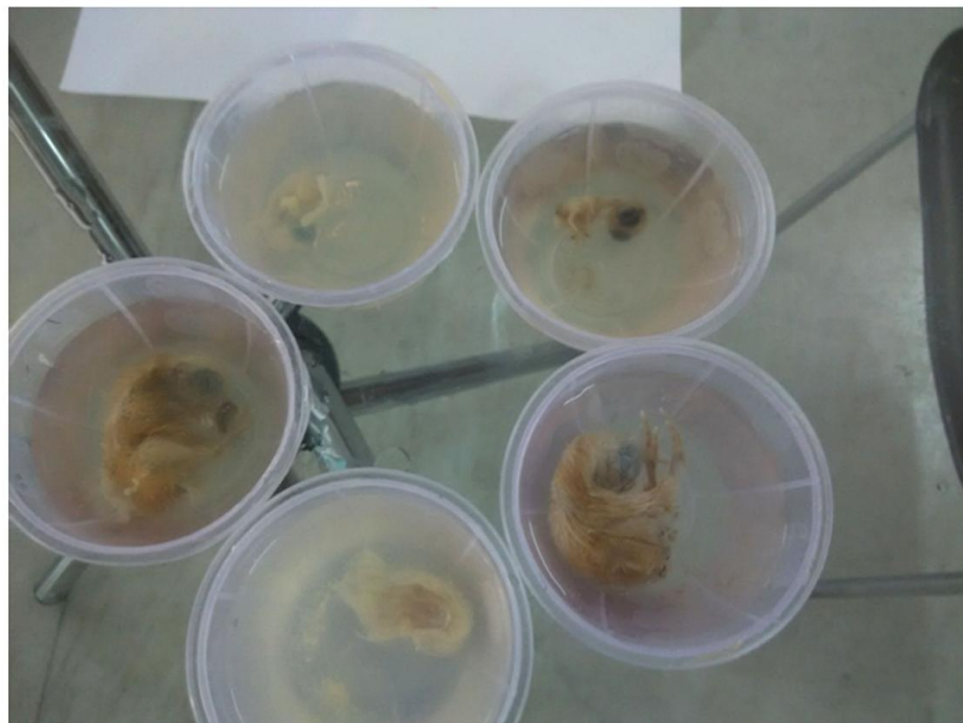e) **DATA ANALYSIS:** The data is analyzed statistically using SPSS software (version 17.0)

### **RESULTS:**

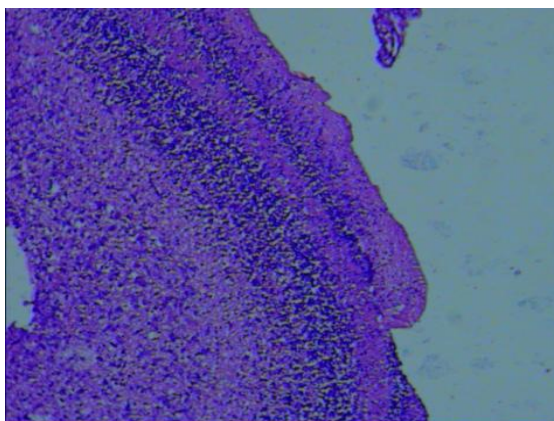
Sodium Valproate administration resulted in a dose dependent massive reduction in number of cells in all layers of cerebellum as compared to the number of cells of cerebellum from control. Sodium Valproate induced cytotoxicity was presented by reduction of cell-cycle resulted in an overall decrease of multiplication activity of nervous tissue.It was clearly associated with reduction of number of cells in all layers of cerebellum.



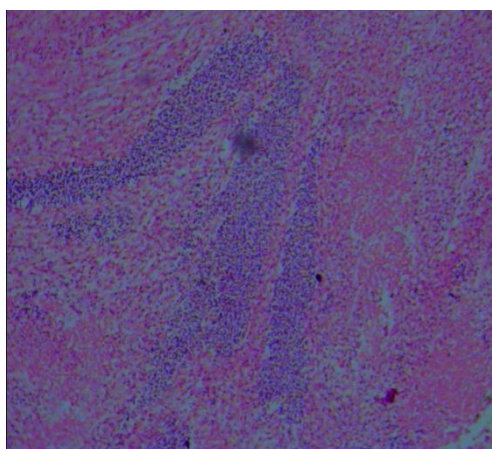
Normal Embryos-Sacrificed at 20 days



**Sodium Valproate injected at 24 hours and sacrificed at 20 days**



**Microscopic Anatomy of Normal Cerebrum-20<sup>th</sup> day**



**Microscopic Anatomy of Cerebrum-Embryo injected with Sodium Valproate-20<sup>th</sup> day**

## DISCUSSION:

Sodium Valproate has most influence on organogenesis stage of development where organs follow a distinct sequence of cell division, migration differentiation and cell death. The drug causes oxidative stress leading to apoptosis. Most frequently results in the failure of the neural tube closure (spina bifida) and may lead to reduced post natal cognitive function in addition to major congenital malformations(8).

The normal chick embryo has shown devastating changes after the administration of Sodium Valproate. The drug administration resulted in a dose dependent massive reduction in the cells of all the layers of cerebrum as compared to the number from control. Sodium Valproate induced cytotoxicity manifested by dose dependent disturbance of cell-cycle resulted in an overall depression of proliferation activity clearly associated with the occurrence of malformations and embryonic death (9). The histological study of normal chick embryo brain-cerebellum tissue was compared with the drug administered chick embryo brain-cerebellum tissue at same age, which showed a gross loss in cellularity.

The loss in the cellularity could be attributed to two factors:

- (1) a decrease in proliferation of brain cells and
- (2) induction of cell death in the brain cells of drug treated embryos.

The results of the present study corroborate both the possibilities.

Cerebellum obtained from sodium valproate treated fetuses upon incubation in vitro showed a decreased proliferative ability (cell number) as compared to cerebellar cells of untreated fetuses. Sodium Valproate produced dose-related Teratogenic effects. The brain cells of fetuses obtained from Sodium Valproate treated mice showed an increased population of cells with typical apoptotic morphology(10).

## REFERENCES:

1. Ma,K,O and Zheny, G.M.(1984). Comparative Anatomy of vertebrates Higher Beijing, Education press(article in Chinese pp: 360- 400.
2. Sturkie.D. (1986) .Avain physiology 3thed. Springer verlag , new York pp:33-36
3. Husband, sand shimizu .(1999).Evolution of the avain visual system .[.Http://luna.cas.edu/-Husband/evolve/default.htm](http://luna.cas.edu/-Husband/evolve/default.htm).
4. Shively, M.J.(1985).Nervous system avain anatomy, veterinary anatomy BASHC comportiv clinical pp: 486.
5. Dyce, K.M;Sack,W,O and Wewsing, C. JG. (1987).Avain Anatomy Text book of veterinary anatomy pp: 772-797 . Fig(8)Transverse section medulla oblongata A-the first zone B-the second zone C-the third zone 800x H&E Fig(6) Transverse section of the cerebellum Awhite matter B-purkinje cells C-granular layer 800x H&E Fig(7) Transverse section of medulla oblongata A-the first zone B-the second zone C-the third zone 300x H&E J.Thi-Qar Sci. Vol.3 (3) Aug./2012 05
6. Dellman,H.D and Meclure,R.C. (1975) .central nervous system Text

- book of Histology ,lea ex and febiger, philadelphia pp : 150-199.
7. Bunyamin,S;Huseyin,A;Bunyami,U; Sinan, C;Sait,B;Suleyman,K and levent,T. (2001).Brain volumes of the lamb ,Rat and Bird do not show hemispheric asymmetry:astereological study.Image .Anat.stereol 20:9-13. 11- Goodmon,IJ and schein M.W.(1974). Birds
  8. Katie Alexandra Lloyd. “ a scientific review:mechanisms of valproate-mediated teratogenesis”Oxford university press,BioscienceHorizons(1-10):volume 6, 2013.
  9. Kelly PG,Regan CM. “study on valproate-induced perturbations of neurulation in the explanted chick embryo.” Toxicology.71(1-2):137-44. 1992.
  10. Kaneko.S.,K.Otani,Y.Fukushima,T.S ato, Y Nomura &Y.Ogawa “transplacental passage and half life of sodium valproate in infants born to epileptic mothers” British Journal of Clinical Pharmacology, 15,1983.
  11. V.Hamburger & H.L. Hamilton; 1951 ,page 55-57.
  12. Ornoy A. Valproic acid in pregnancy: how much are we endangering the embryo and fetus? Reproductive Toxicology.28(1):1-10. 2009
  13. Alexander.F.W “Sodium valproate and pregnancy.” Arch. Dis. Child., 54, 240. 1979.
  14. Dickinson et al. Transmission of valproic acid (Depakene) across the placenta: Half-life of the drug in mother and baby. J. Pediatr., 94, 832. 1979.
  15. Dickinson's group (1979) and Nau's group, “Transmission of valproic acid (Depakene) across the placenta: Half-life of the drug in mother and baby”. J. Pediatr., 94, 832. 1982.
  16. Cecilie M Lander “Antiepileptic drugs in pregnancy and lactation.” 2006.
  17. N Adab, U Kini et al.“The longer term outcome of children born to mothers with epilepsy”Journal of Neurology ,Neurosurgery Psychiatry;75:1575-1583,2004.
  18. Somsak Tiamkao“The efficacy of intravenous sodium valproate and phenytoin as the first-line treatment in status epilepticus: a comparison study”,Bio Medical Central,Neurology,13:98, 2013.
  19. G.Mawer et al. studied “Pregnancy with epilepsy: Obstetric and neonatal outcome of a controlled study” 2010.
  20. Whittle,B.A. Pre-clinical teratological studies on sodium valproate(epilim) and other anticonvulsants.In Clinical and Pharmacological Aspects of Sodium Valproate (epilim) in the treatment of epilepsy,ed.Legg.N.J.pp.105-110.Tunbridge Wells:MCS Consultants.1976
  21. Roy G. Beran “The ethics of excluding women who become pregnant while participating in clinical trials of anti-epileptic medications”Seizure, The Journal of British Epilepsy Association,563-570,2006.
  22. N Adab, A Jacoby, D Smith, D Chadwick “Additional educational needs in children born to mothers with epilepsy” Journal of neurology,neurosurgery,psychiatry:70:1 5-21, 200